



# Behind the Screens

Missouri Department of Health and Senior Services  
Newborn Screening Program

April 2022 ★ Missouri Dept. of Health and Senior Services ★ [www.health.mo.gov](http://www.health.mo.gov) ★ Volume 5 Number 2

## Featured Disorder

Adrenoleukodystrophy (ALD) is an X-linked genetic disease that most severely affects males. This disease mainly affects the nervous system and the adrenal glands. ALD often causes progressive loss of the myelin sheath, the fatty covering that acts as an insulator and surrounds the nerves in the brain and spinal cord. This can cause a variety of neurological problems including cognitive, mobility and sensory issues. If left untreated, the severe form of ALD (cerebral ALD) can lead to critical and irreversible disabilities that can require continuous and extraordinary care and ultimately lead to death. ALD may also cause adrenal insufficiency, a deficiency of certain hormones due to damage to the adrenal glands. Adrenal insufficiency can cause weakness, weight loss, skin changes, vomiting and coma.

### Causes:

ALD is caused by a mutation found on the ABCD1 gene located on the X chromosome. Because ADL is an X-linked disorder, women who are carriers of ALD have a 50% chance of passing the affected X chromosome on to their children. Men can also be carriers and can pass the affected gene on to their daughters.

### There are several different forms of ALD:

Adrenal Insufficiency affects about 90% of males with ALD. Adrenal insufficiency can present within the first year of life and can be deadly if not treated appropriately.

Cerebral ALD (cALD) affects the brain, most often in childhood, but can also occur in adolescence and adulthood. Childhood cALD generally occurs between four and 10 years of age when seemingly normal, healthy boys suddenly begin to regress. Initial symptoms may include minor behavior problems such as withdrawal or difficulty concentrating, vision problems or coordination issues. As the disease progresses, symptoms may include blindness, deafness, seizures, loss of muscle control and progressive dementia. Typically, death occurs within two to five years of diagnosis.

Adrenomyeloneuropathy (AMN) begins between early adulthood and middle age. Affected individuals may develop progressive stiffness and weakness in the legs, difficulties with coordination and speech, adrenal insufficiency, sexual dysfunction and bladder issues. Individuals with brain involvement may also experience behavior changes, vision and hearing problems or seizures. In some severely affected individuals, AMN can lead to early death.

*continued on next page*

p2

Did You Know?

p3

Patient Spotlight

p4

Tech Tips

### Prevalence:

One in 17,000 people are affected. Although ALD is X-linked, mostly affecting boys and men, women can be carriers for this disease and can experience neurological symptoms later in adulthood.

### Treatment:

Stem cell and cord blood transplant can halt the progression of cALD if the disease is detected early. However, once myelin has been damaged; it cannot be repaired or restored with this treatment. Early diagnosis through newborn screening allows for proactive treatment as well as consistent care and monitoring of disease progression. Adrenal insufficiency is effectively treated with lifelong hormone replacement therapy.

On December 1, 2021, the Missouri Newborn Screening Program began the implementation phase to screen for ALD. While all babies will be screened during the implementation phase, ALD screening results will not appear on the standard newborn screening laboratory reports. Once more permanent reference ranges are established, laboratory reports will be standardized to contain this information. All abnormal ALD results will be reported to the baby's physician of record.

For more information on ALD visit:  
[NIH-Rare Disease](https://www.nih.gov/rare-disease)  
[aldnewbornscreening.org](https://aldnewbornscreening.org)

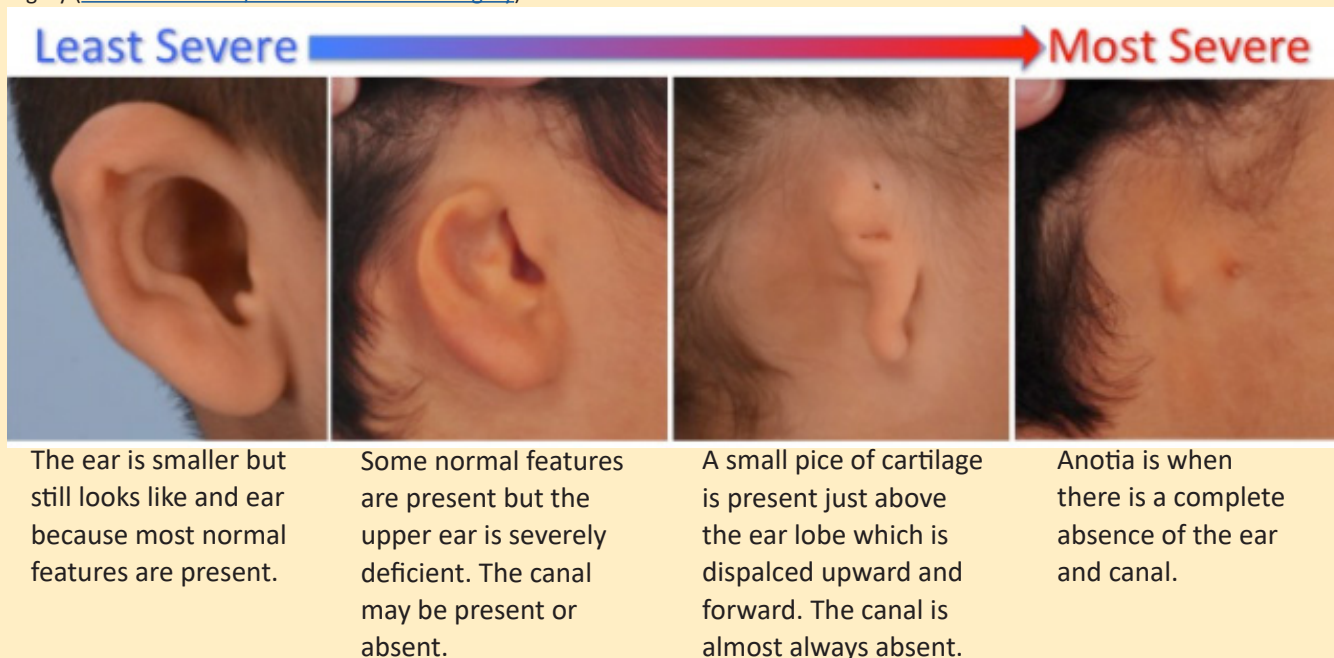
## Did You KNOW?

Microtia is a congenital deformity of the ear where the outer ear does not develop fully during the first trimester of pregnancy. Microtia can occur with other congenital abnormalities, but is most often seen as an isolated, independent deformity and is often associated with a small or absent ear canal known as aural atresia. Microtia varies in severity from the ear appearing formed but small to the ear being completely absent. This is known as anotia. When anotia is present and atresia is complete, conductive

hearing loss will be present. Any degree of microtia or atresia can be associated with additional middle ear deformities which also can cause permanent conductive hearing loss. Newborn hearing screening is often not possible for microtic or atretic ears. In these cases the hearing screening should be reported as a "refer" and family informed to seek consultation with an audiologist. Ear deformities should be noted on the screening form.

### Spectrum of Microtia Severity

photo courtesy of Ear Reconstruction — Dallas Plastic Surgeon specializing in Rhinoplasty, Septoplasty, Cleft Rhinoplasty, Cleft Lip Revision and Ear Surgery ([drderderian.com/ear-reconstruction-surgery](http://drderderian.com/ear-reconstruction-surgery))






# Patient

## Spotlight

### JACOB GLADBACH



Jacob Gladbach is an 18-year-old with Adrenoleukodystrophy (ALD), diagnosed at age 14. When he was in 8<sup>th</sup> grade, he had three episodes with auras and odd behavior. His symptoms were vague but concerning. A doctor recommended an MRI which detected brain damage. This is when we first heard the acronym “ALD” and our lives were forever changed.

We were referred to St. Louis Children’s Hospital and found out that Jacob has one of the more rare cases of “late onset ALD. As a result his brain damage was more severe prior to detection, and doctors were worried Jacob may not have been a good candidate for the stem cell transplant based on the amount of brain damage he had already suffered.

At this point everything kicked into high gear! We went from freshman football workouts to a seemingly terminal diagnosis. We move to St. Louis in July of 2018 and spent the next six months prepping for the stem cell transplant. He was hospitalized for about a week to prep for the transplant and nearly 50 days after the transplant. Then we stayed in an apartment at the Ronald McDonald House near the hospital for another two months. During the initial hospital stay, he had a grand mal seizure and then began to lose his eyesight. Due to the brain damage, by the end of October Jacob had lost his eyesight completely. In April of 2019 Jacob was suffering from severe esophagitis from graft versus host disease which can occur when the new donor stem cells attack the recipient. At a scheduled EGD his esophagus was perforated, and he spent another 20 days in the hospital. Followed by four more inpatient stays in May and June fighting off infections.

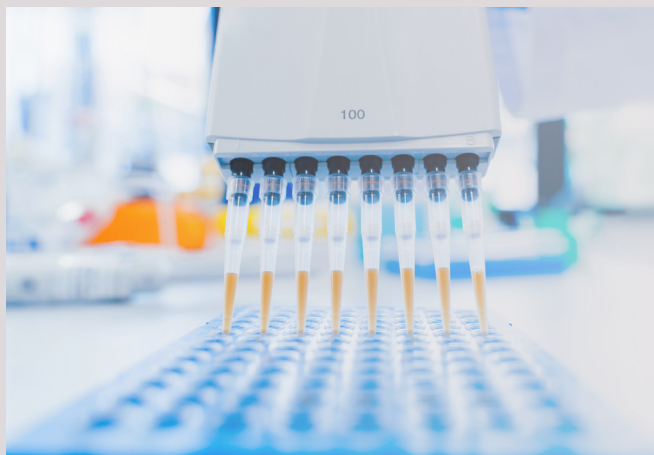Jacob started back to school in the fall of 2019. He still occasionally suffers from grand mal seizures,

severely affecting his balance and coordination, coupled with his blindness, do not allow him to be as independent as he once was, but he is still living a full life. He loves his cat, and his music, and we are figuring it out as we go. It has been a long hard road, but with a happier ending than we thought.

I worked for many years as the Unit Chief of Microbiology for the Missouri State Public Health Laboratory (MOSPHL) and was asked to be on the Department of Health and Senior Services Genetics Advisory Committee and speak to the panel of experts, sharing Jacob’s story of his late diagnosis. The members of the MOSPHL Newborn Screening Unit were moved by Jacob’s story, and asked if they could name the piece of equipment doing the ALD screening after him. So now “Jacob” helps the lab screen for ALD for all Missouri newborns.

--Steve Gladbach (Jacob’s Dad)





# Tech Tips

- It is vitally important to complete the newborn blood spot screening form completely and accurately each and every time. Include both FIRST and LAST name of the provider caring for the baby after discharge, collection date and time, birth date and time of birth. All information provided on the form is important for the laboratory to provide accurate screening results. Missing information can lead to delays in follow-up of abnormal results and prevent timely treatment of life threatening disorders.
- Once the dried blood spot specimen is collected, it is equally important to dry, store and transport the specimen to the laboratory using the appropriate modality.
  - o Triple-packaging system provides mail handlers with reasonable safety from occupational exposure to non-regulated infectious materials and maintains optimal specimen integrity.
    - » Primary container is the filter paper matrix that contains the absorbed and dried blood.
    - » Secondary container encloses the filter paper. Most collection devices use a fold-over flap that covers the dried filter paper.
    - » The secondary container should then be placed in an outer envelope of sturdy, high-quality paper providing the third level of containment. (Please do not send specimens in Zip top or biohazard bags; as they do not allow proper internal air circulation and can cause moisture buildup and specimen degradation).




## MISSOURI DEPARTMENT OF HEALTH AND SENIOR SERVICES

**Bureau of Genetics and Healthy Childhood**  
Newborn Blood Spot, Hearing, and Critical Congenital  
Heart Disease Programs  
573.751.6266 or 800.877.6246

**Missouri State Newborn Screening Laboratory**  
573.751.2662

[www.health.mo.gov/newbornscreening](http://www.health.mo.gov/newbornscreening)

 @HealthyLivingMo  @HealthyLivingMo

An EO/AA employer: Services provided on a nondiscriminatory basis.  
Hearing- and speech-impaired citizens can dial 711.

